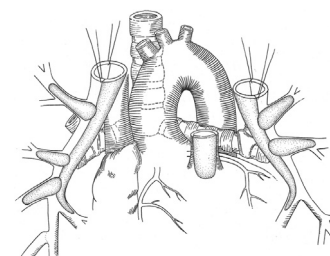


# Surgical Techniques for Repair of Peripheral Pulmonary Artery Stenosis



Richard D. Mainwaring, MD, and Frank L. Hanley, MD

Peripheral pulmonary artery stenosis (PPAS) is a rare form of congenital heart disease that is most frequently associated with Williams and Alagille syndromes. These patients typically have systemic level right ventricular pressures secondary to obstruction at the lobar, segmental, and subsegmental branches. The current management of patients with PPAS remains somewhat controversial. We have pioneered an entirely surgical approach for the reconstruction of PPAS. This approach initially entailed a surgical patch augmentation of all major lobar branches and effectively reduced the right ventricular pressures by more than half. This was the first report demonstrating an effective approach to this disease. Over the past 5 years, we have gradually evolved our technique of reconstruction to include segmental and subsegmental branch stenoses. An important technical aspect of this approach entails the division of the main pulmonary and separation of the branch pulmonary arteries to access the lower lobe branches. Pulmonary artery homograft patches are used to augment hypoplastic pulmonary artery branches. In addition, we perform a Heinecke-Miculicz-type ostioplasty for isolated ostial stenoses. The technical details of the surgical approach to PPAS are outlined in this article and can also be used for other complex peripheral pulmonary artery reconstructions.



An illustration demonstrating key steps in the surgical technique for reconstruction of peripheral pulmonary artery stenosis.

## Central Message

This article provides a detailed description of the surgical techniques that have been developed for the surgical reconstruction of peripheral pulmonary artery stenosis.

**Semin Thoracic Surg 28:418–424** © 2016 Elsevier Inc. All rights reserved.

**Keywords:** Congenital heart disease, Pulmonary arteries

## INTRODUCTION

Peripheral pulmonary artery stenosis (PPAS) is a rare and complex form of congenital heart disease that is associated with Williams and Alagille syndromes.<sup>1–3</sup> The natural history of PPAS is highly dependent on the degree of obstruction.<sup>4–7</sup> Mild cases have a favorable prognosis and may demonstrate spontaneous regression of the peripheral stenosis.<sup>8</sup> These mild cases rarely need any type of intervention. In contrast, severe PPAS is characterized by multiple stenoses of lobar and segmental branches and tends to progress over time. Severe PPAS results in right ventricular hypertension, right ventricular hypertrophy, and eventually right ventricular failure. The severe cases of PPAS almost invariably require intervention to alleviate the adverse consequences of high right ventricular pressures.<sup>9,10</sup>

Division of Pediatric Cardiac Surgery, Lucile Packard Children's Hospital, Stanford University School of Medicine, Stanford, California

Address reprint requests to Richard D. Mainwaring, MD, Division of Pediatric Cardiac Surgery, Lucile Packard Children's Hospital, Stanford University School of Medicine, 300 Pasteur Dr, Falk CVRC, Stanford, CA 94305. E-mail: [mainwaring@stanford.edu](mailto:mainwaring@stanford.edu)

The optimal management of patients with severe PPAS remains controversial.<sup>11</sup> Many centers have advocated a “multimodality approach” that includes surgical augmentation of the central pulmonary arteries and catheter-based treatment of the more distal stenosis.<sup>12,13</sup> However, there is little evidence that this multimodality approach has any lasting efficacy for this disease. The Achilles heel of catheter-based treatment has proven to be the ineffectiveness of relieving obstruction at the lobar and segmental level.

In 2012, we reported a series of 16 patients who underwent surgical reconstruction for severe PPAS.<sup>14</sup> This was the first report in the literature advocating an entirely surgical approach to this disease. The surgical technique for reconstruction of PPAS is a technically challenging procedure because of the need to access all lobar and segmental branches. This article describes our current surgical approach for peripheral pulmonary artery reconstruction.

## SURGICAL TECHNIQUE

A median sternotomy incision is performed, and the pericardium is opened. The main pulmonary artery as well as the right and left branch pulmonary arteries is dissected free

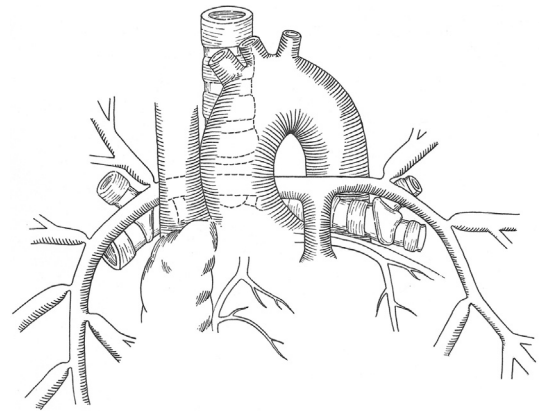
from the surrounding structures (Fig. 1). The intrapericardial portion of this dissection is performed in a standard fashion. Before the extrapericardial portion of the pulmonary artery dissection, both pleural spaces are opened, and the course of both phrenic nerves is marked with fine prolene sutures. The lobar and segmental branches are sequentially identified, and the external anatomical appearance is compared with the preoperative angiogram.

It is imperative to perform the entire surgical dissection before the administration of heparin to achieve complete hemostasis. In addition, we have noted a significant incidence of intraparenchymal hemorrhage, if the dissection is performed after the patient is anticoagulated.

Cardiopulmonary bypass is instituted, and the patient is cooled to 25°C. This degree of hypothermia results in a significant reduction in metabolic rate, permitting the safe reduction in pump flow with an important physiological effect of a commensurate decrease in collateral flow to the lung. A vent catheter is inserted through the right superior pulmonary vein into the left ventricle. The main pulmonary artery is divided distally, and the right and left branch pulmonary arteries are separated. Neuroclips are placed on each of the lobar branches to prevent backbleeding.

The right and left branch pulmonary arteries are incised starting along the inferior aspect of the artery. This incision is continued distally following the medial border of the artery and extended into the medial basal segment of each lower lobe. Stay sutures are placed at the upper edges of the branch pulmonary arteries to facilitate exposure (Fig. 2). The orientation of this incision is critical as it results in the opening in each artery facing into the free space away from the superior pulmonary veins and bronchi. Other potential orientations of this incision uniformly result in a “competition for space” with adjoining structures. Specifically, an anterior incision would result in competing for space with the upper lobe pulmonary veins. A superior incision would result in competition with the distal bronchi as well as the origin of the lobar branches, whereas a posterior incision would compete with the proximal bronchus.

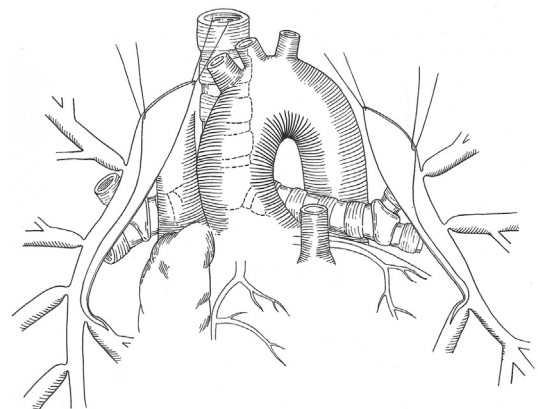
Each of the peripheral stenoses is then addressed sequentially. Segmental and subsegmental stenoses are often amenable to surgical ostioplasty using a Heineke-Miculicz technique (Fig. 3A), particularly in the presence of ostial stenosis with a normal distal vessel (Fig. 3B). The vessel is probed with a metal dilator to get a “feel” for the severity and extent of the stenosis (Fig. 3C). The carina of the



**Figure 1.** An illustration demonstrating typical anatomy associated with peripheral pulmonary artery stenosis (PPAS). There are multiple lobar and segmental stenoses. (Reproduced with permission from Mainwaring et al.<sup>17</sup>)

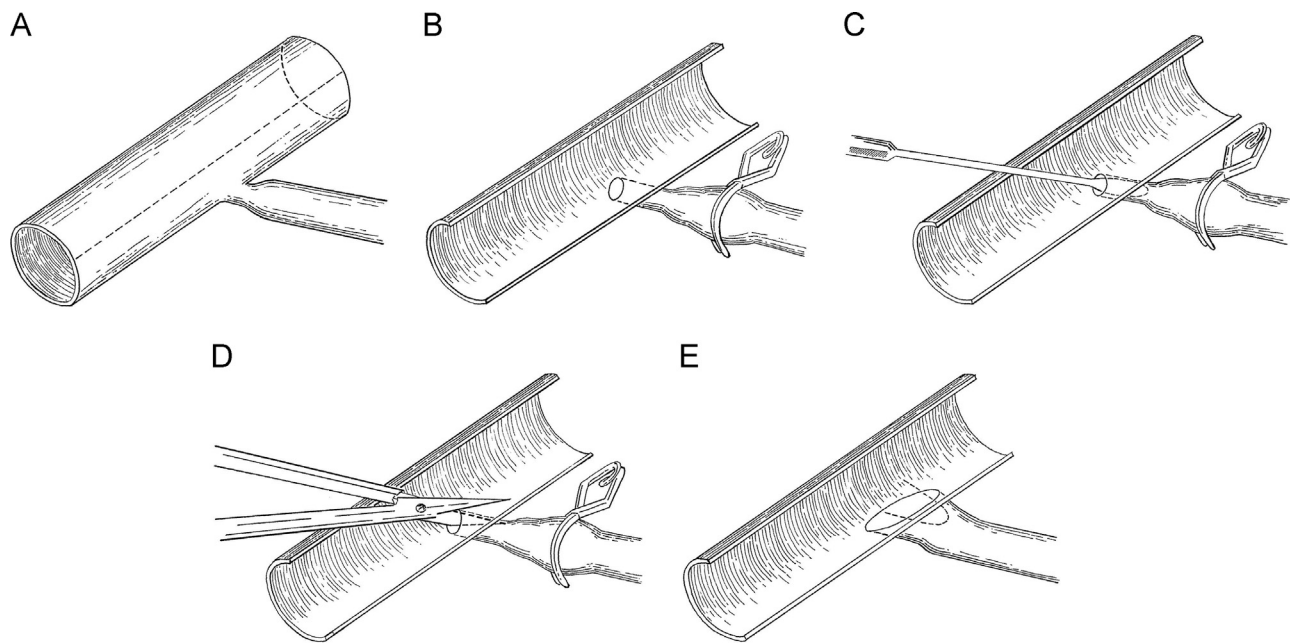
vessel is then incised with fine scissors to a point beyond the limits of the stenosis (Fig. 3D). The incision is then closed in a transverse direction (90° to the direction of the incision) with 8-0 prolene sutures (Fig. 3E).

There are circumstances when the anatomy of a peripheral pulmonary artery would not be amenable to ostioplasty. Specifically, in the setting of a longer stenosis, an ostioplasty would not adequately address the full extent of the narrowing leading to the 2 distal branches (Fig. 4A). This



**Figure 2.** An illustration demonstrating the initial step in the reconstruction of PPAS. The main pulmonary artery is divided, as are the right and left branch pulmonary arteries. An incision is made along the inferior aspect of the proximal branch pulmonary arteries and continuing along the medial border of the lower lobe artery. (Reproduced with permission from Mainwaring et al.<sup>17</sup>)

## PERIPHERAL PA RECONSTRUCTION



**Figure 3.** (A) Anatomy of a segmental branch pulmonary artery with severe stenosis, located at the ostia. (B) The branch pulmonary artery is opened to reveal the ostia of the segmental branch. (C) The ostia is probed to assess the severity and extent of the stenosis. (D) The carina is incised to a point beyond the level of stenosis. (E) The incision is repaired in a transverse direction with 8-0 prolene suture.

disparity in size can be discerned visually and confirmed by probing the proximal and distal vessels. In this circumstance, the main artery is opened (Fig. 4B), and the side branch is incised beyond the bifurcation (Fig. 4C). The side branch is augmented with a patch of pulmonary artery homograft (Fig. 4D).

The primary longitudinal incisions in the branch pulmonary arteries are then augmented with long pulmonary homograft patches, as shown in Figure 5. The reconstructed branch pulmonary arteries are then sewn together end to end. The main pulmonary artery is augmented with a patch of pulmonary artery homograft. The main pulmonary artery is then anastomosed to the reconstructed branch pulmonary arteries to complete the operation (Fig. 6).

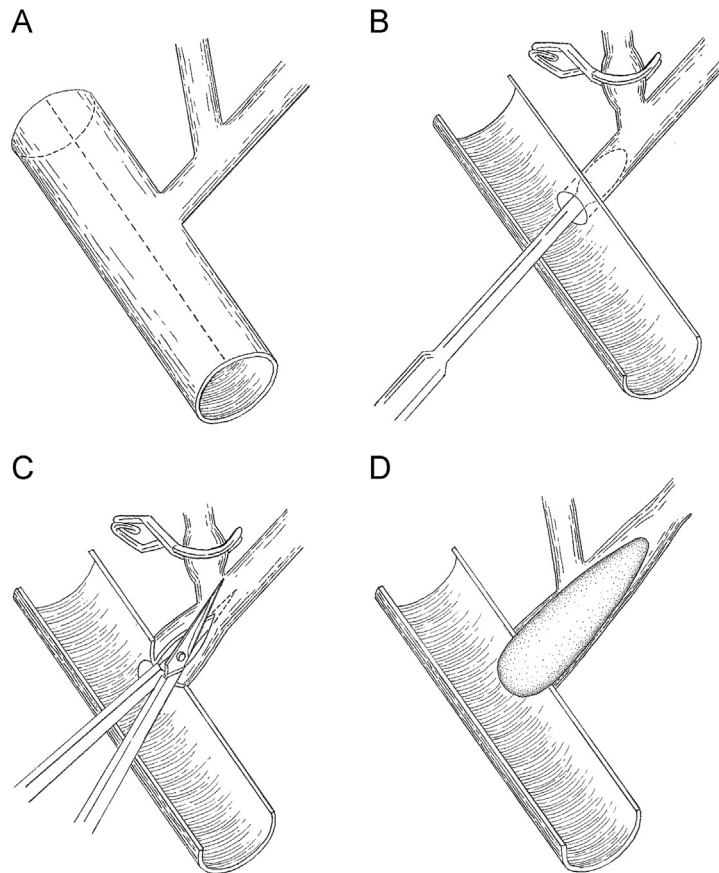
There are specific instances in which we reconstruct the central pulmonary artery confluence anterior to the aorta using a LeCompte maneuver. The primary indication for a LeCompte is the absence of adequate space for the branch pulmonary arteries to traverse through the aortopulmonary window. This situation may arise when the native branch pulmonary arteries are hypoplastic and this space is usurped by other adjoining structures including the ascending aorta, descending aorta, and tracheobronchial tree. There may also be limited space in the aortopulmonary window after

reconstruction of the ascending aorta or aortic arch in patients with Williams syndrome. This option should be entertained in all patients undergoing PPAS repair and was used in one-quarter of the patients in our series.

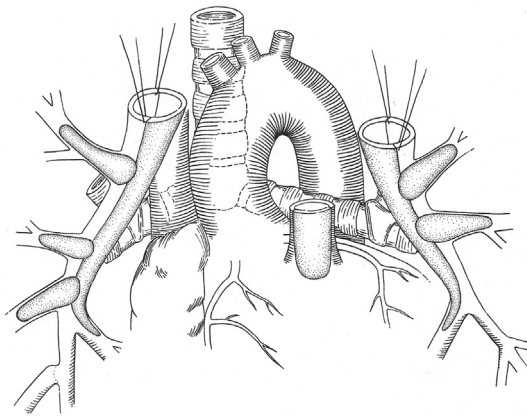
The patients are rewarmed during the finishing stages of the reconstruction. Virtually all of the patients have an extremely hypertrophied right ventricle because of the systemic level pressures that were present preoperatively. In view of this, we specifically avoid the administration of epinephrine and use only low-dose dopamine and milrinone. The administration of catecholamines may exacerbate the gradient across the right ventricular outflow tract, which invariably is present to a modest extent. Two transthoracic pressure lines are placed to monitor left atrial and right ventricular pressures. The patient is weaned from cardiopulmonary bypass, and transesophageal echocardiography is performed to assess ventricular function and presence or absence of gradient across the right ventricular outflow tract.

### SURGICAL EXPERIENCE AND RESULTS

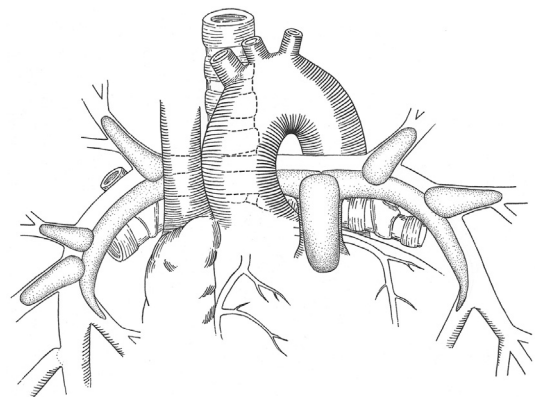
Overall, 38 patients have undergone surgical reconstruction of PPAS at our center between 2002 and 2016. Furthermore, 20 patients had Williams syndrome and 12 had Alagille syndrome, accounting for the preponderance (86%) of patients. For the



**Figure 4.** (A) Anatomy of a long-segment stenosis of a branch pulmonary artery. The proximal vessel is the same size as the 2 distal vessels, indicative of a relative narrowing. (B) The main artery is opened longitudinally to reveal the ostium of the side branch. This vessel can be probed to evaluate the extent and severity of the narrowing. (C) The side branch is incised beyond the bifurcation. (D) The side branch is augmented with a patch of pulmonary artery homograft. This is sutured in place with 8-0 prolene suture.



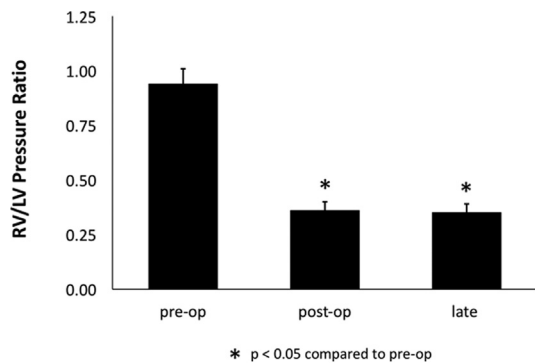
**Figure 5.** An illustration demonstrating surgical reconstruction of PPAS. An ostioplasty has been performed to the basilar segment of the right lower lobe. Separate homograft patches are performed to augment the segmental and lobar branch stenoses. A long homograft patch is then sutured in place to augment the branch pulmonary arteries. (Reproduced with permission from Mainwaring et al.<sup>17</sup>)



**Figure 6.** An illustration demonstrating re-establishment of continuity between the right and the left branch pulmonary arteries and reanastomosis to the reconstructed main pulmonary artery. (Reproduced with permission from Mainwaring et al.<sup>17</sup>)



## PERIPHERAL PA RECONSTRUCTION



**Figure 7.** Depiction of the right ventricle to aortic peak systolic pressure ratios before surgery, immediately after surgery, and at mid-term follow-up for the 38 patients in this series.

remaining 6 patients, 1 had pulmonary calcinosis syndrome, 1 had arterial tortuosity syndrome, 1 had Noonan syndrome, and 3 had no identifiable genetic syndrome.

The average preoperative right ventricular or left ventricular peak systolic pressure ratio was  $0.94 \pm 0.07$  (range: 0.72-1.30). The median age at surgery was 14 months, ranging from 2 months to 13 years.

The patients underwent an average of  $12 \pm 8$  homograft patch augmentations or Heineke-Miculicz ostioplasties (range: 5-32). The average cardiopulmonary bypass time was  $285 \pm 164$  minutes (range: 78-669 minutes). Of the 19 patients, 13 with Williams syndrome underwent concomitant

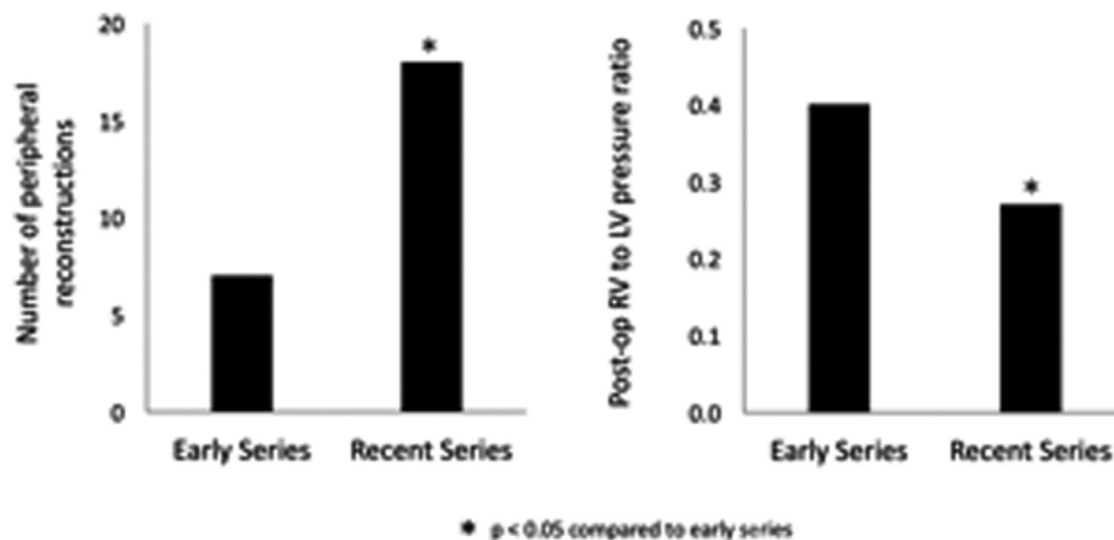
reconstruction of the ascending aorta for supravalvar aortic stenosis, and of these 13 patients, 5 had patch augmentation of the left main coronary ostium.

Postoperatively, the average right ventricle to aortic peak systolic pressure ratio was  $0.36 \pm 0.07$  (range: 0.19-0.54). This represents a 62% decrease in right ventricle to left ventricle pressure ratio compared with the preoperative values (Fig. 7). There was no discernible difference in either the preoperative or postoperative right ventricle to aortic pressure ratios among the various syndromes.

There was 1 operative mortality (2.5%) in a patient with Williams syndrome, severe PPAS, and supravalvar aortic stenosis with a 70-mm Hg gradient. This patient underwent repair of both the PPAS and ascending aorta but postoperatively had depressed left ventricular function, developed multi-system organ dysfunction, and eventually did not survive.

One patient in our series developed a severe lung reperfusion injury and required institution of extracorporeal membrane oxygenation support for lungs for 4 days. This patient was successfully weaned from extracorporeal membrane oxygenation and demonstrated gradual resolution of the lung reperfusion injury. This patient was discharged from the hospital on the 22nd postoperative day.

Of the 38 patients, 35 underwent a single-stage repair, whereas 3 patients had a staged approach. The decision to pursue a staged approach was related to specific circumstances for each patient. One



**Figure 8.** (A) Bar graph demonstrating the number of peripheral pulmonary artery reconstructions performed in the first portion of the surgical series compared with patients who have undergone an extended approach to segmental disease. (B) Bar graph demonstrating the right ventricle to aortic pressure ratios in the first portion of the series compared with patients who underwent an extended approach to segmental disease.

Illustrations drawn by Erin Anne Mainwaring.

patient with Alagille syndrome had a marked disparity in blood flow to the right (85%) vs left (15%) lungs owing to a tight ostial stenosis of the left branch pulmonary artery. This patient underwent repair of the left side first followed by the right side a year later.

A second patient (also with Alagille) presented with PPAS and severe liver dysfunction. This patient was in need of a liver transplant, and there was concern that the patient might not tolerate the lengthy bypass time that would be required for a complete repair. This patient underwent repair of the left lung to reduce right ventricular pressures. The patient subsequently underwent a successful liver

transplant followed by repair of the right lung. A third patient had undergone a thoracotomy procedure at an outside institution. This patient underwent a staged approach at our institution with re-repair of the previously operated side followed by repair of the contralateral lung.

The average duration of follow-up is  $4 \pm 3$  years. There has been no delayed mortality in the 37 operative survivors. None of the patients have required reoperation. One patient subsequently had balloon angioplasty of a residual proximal branch pulmonary artery stenosis. The right ventricle to aortic pressure ratios have remained stable over time, with an average ratio of  $0.35 \pm 0.04$ .

- Williams JC, Barratt-Boyes BG, Lowe JB: Supravalvular aortic stenosis. *Circulation* 24: 1311-1318, 1961
- Beuren AJ, Schulze C, Eberle P, et al: The syndrome of supravalvular aortic stenosis, peripheral pulmonary stenosis, mental retardation and similar facial appearance. *Am J Cardiol* 13:471-483, 1964
- McElhinney DB, Krantz ID, Bason L, et al: Analysis of cardiovascular phenotype and genotype-phenotype correlation in individuals with a JAG1 mutation and/or Alagille syndrome. *Circulation* 106:2567-2574, 2002
- Giddins NG, Finley JP, Nanton MA, et al: The natural course of supravalvular aortic stenosis and peripheral pulmonary artery stenosis in Williams' syndrome. *Br Heart J* 62:315-319, 1989
- Wren C, Oslizlok P, Bull C: Natural history of supravalvular aortic stenosis and pulmonary artery stenosis. *J Am Coll Cardiol* 15: 1625-1630, 1990
- Wessel A, Pankau R, Kececioglu D, et al: Three decades of follow-up of aortic and pulmonary vascular lesions in the Williams-Beuren syndrome. *Am J Med Genet* 52:297-301, 1994
- Kim YM, Yoo SJ, Choi JY, et al: Natural course of supravalvular aortic stenosis and peripheral pulmonary arterial stenosis in Williams' syndrome. *Cardiol Young* 9:37-41, 1999
- Miyamura H, Watanabe H, Tatebe S, et al: Spontaneous regression of peripheral pulmonary artery stenosis in Williams syndrome. *Jpn Circ J* 60:311-314, 1996
- Katz NM, Blackstone EH, Kirklin JW, et al: Late survival and symptoms after repair of tetralogy of Fallot. *Circulation* 62:403-410, 1982
- Kirklin JW, Blackstone EH, Jonas RA, et al: Morphologic and surgical determinants of outcome events after repair of tetralogy of Fallot and pulmonary stenosis. A two-institution study. *J Thorac Cardiovasc Surg* 103:706-723, 1992
- Gandy KL, Tweddell JS, Petech AN: How we approach peripheral pulmonary stenosis in Williams-Beuren syndrome. *Semin Thorac Cardiovasc Surg Pediatr Card Surg Ann* 12: 118-121, 2009
- Trivedi KR, Benson LN: Interventional strategies in the management of peripheral pulmonary artery stenosis. *J Interven Cardiol* 16: 171-188, 2003
- Geggel RL, Gauvreau K, Lock JE: Balloon dilation angioplasty of peripheral pulmonary stenosis associated with Williams syndrome. *Circulation* 103:2165-2170, 2001
- Monge M, Mainwaring RD, Sheikh AY, et al: Surgical reconstruction of peripheral pulmonary artery stenosis in Williams and Alagille syndromes. *J Thorac Cardiovasc Surg* 145: 476-481, 2013
- Mainwaring RD, Sheikh AY, Punnett R, et al: Surgical outcomes for patients with pulmonary atresia/major aortopulmonary collaterals and Alagille syndrome. *Eur J Cardiothorac Surg* 42 (2):235-241, 2012
- Mainwaring RD, Reddy VM, Peng L, et al: Hemodynamic assessment after complete repair of pulmonary atresia/major aortopulmonary collaterals. *Ann Thorac Surg* 95(4): 1397-1402, 2013
- Mainwaring RD, Ibrahimiyeh AN, Hanley FL: Surgical techniques for repair of peripheral pulmonary artery stenosis and other complex peripheral reconstructions. *Ann Thorac Surg* 102:e181-e183, 2016
- Stamm C, Friehs I, Moran AM, et al: Surgery for bilateral outflow tract obstruction in elastin arteriopathy. *J Thorac Cardiovasc Surg* 120: 755-763, 2000
- Burch TM, McGowan FX, Kussman BD, et al: Congenital supravalvular aortic stenosis and sudden death associated with anesthesia: What's the mystery? *Anesthesia* 107:1848-1854, 2008
- Formigari R, Michielon G, Digillio MC, et al: Genetic syndromes and congenital heart defects: How is surgical management affected? *Eur J Cardiothorac Surg* 35:606-614, 2009
- Michielon G, Marino B, Formigari R, et al: Genetic syndromes and outcome after surgical correction of tetralogy of Fallot. *Ann Thorac Surg* 81:968-975, 2006
- Blue GM, Mah JM, Cole AD, et al: The negative impact of Alagille syndrome on survival of infants with pulmonary atresia. *J Thorac Cardiovasc Surg* 133:1094-1096, 2007

### DISCUSSION

Reconstruction of PPAS is technically quite challenging because of the need to address the extrapericardial stenoses to the middle and lower lobes. Our center has acquired an extensive experience with extrapericardial pulmonary artery surgery in patients with pulmonary atresia with ventricular septal defect and major aortopulmonary collateral arteries.<sup>15,16</sup> It was this broad experience with peripheral pulmonary artery reconstruction that was subsequently applied to PPAS.

The surgical approach that we use for PPAS reconstruction has evolved considerably over the past 5 years. Our initial experience concentrated on repairing the lobar branch pulmonary artery stenoses along with augmentation of the central and main pulmonary arteries as needed.<sup>14</sup> This approach entailed a median of 7 peripheral pulmonary artery patch augmentations and resulted in a 57% reduction in right ventricle to aortic pressure ratios. However, we also recognized that there were significant stenoses at the segmental and subsegmental levels that were not able to be addressed with this original approach. Therefore, we sought to expand our surgical armamentarium to be able to access and address the more distal disease.

Our current surgical technique includes the separation of the right and left branch pulmonary arteries to access the distal branches and underside of the arteries.<sup>17</sup> Homograft patches are then used to “anchor” the pathway to the lower lobe branches. Each segmental branch is sequentially assessed visually and by passing probes through the ostia into the distal vessel. It is not uncommon to find nearly every segmental branch affected by this disease and to require reconstruction. The 2 principal methods for reconstruction include homograft patch augmentation in the circumstance of long-segment stenosis and surgical ostioplasty for localized ostial disease. The Heinecke-Miculicz ostioplasty technique can also be applied to subsegmental ostial disease and has effectively extended our approach to address more distal abnormalities.

The current approach to PPAS has been implemented over the past 5 years to address disease at the segmental and subsegmental branches.

The patients who have undergone this extended approach underwent a median of 18 peripheral pulmonary artery reconstructions or two and a half times the number performed in the earlier part of our series (Fig. 8). The extended surgical approach resulted in a 72% reduction in right ventricle to aortic pressure ratios compared with 55% in our original approach. We believe that the physiological benefits of the extended surgical approach provide a vindication of this method and justify the additional time that it takes to perform this procedure.

Despite the fact that the name “PPAS” presents the appearance of a single anatomical entity, it is evident that there is considerable diversity from patient to patient. Most patients with Williams syndrome and PPAS have associated supravalvar aortic stenosis,<sup>18</sup> with a subset of these demonstrating left main coronary artery ostial disease.<sup>19</sup> In contrast, patients with Alagille syndrome do not have aortic or coronary abnormalities but frequently have complex, multisystem organ problems (most notably liver dysfunction) that increase the risk of surgical procedures.<sup>20-22</sup> Most patients with PPAS have small, thickened main and central branch pulmonary arteries. However, more distally, some patients have predominantly ostial disease (amenable to ostioplasty), whereas others have longer segment tubular stenoses (amenable to homograft patch augmentation). Our experience would suggest that there is no discernible difference in peripheral pulmonary artery phenotype when comparing patients with Williams syndrome, Alagille syndrome, and the smaller group of patients with no identifiable syndrome. The data would also indicate that there is no significant difference in either preoperative or postoperative right ventricle to left ventricle pressure ratios comparing Williams or Alagille syndromes.

In summary, this report provides a description of our technical approach to the surgical reconstruction of PPAS. This technique is also applicable to other complex reoperative peripheral pulmonary artery surgeries including patients with pulmonary atresia or ventricular septal defect or major aortopulmonary collateral arteries and residual peripheral architectural stenosis.